



Dose and administration of intracameral moxifloxacin for prophylaxis of postoperative endophthalmitis

Steve A. Arshinoff, MD, FRCSC, Milad Modabber, MD, MSc

PURPOSE: To review current and past practices of intracameral antibiotic administration for infection prophylaxis in cataract surgery; to review the benefits and liabilities of available prophylactic drugs, dosage determination, and administration protocols; and to devise an optimum dose and administration protocol for intracameral moxifloxacin.

SETTING: Humber River Hospital and the University of Toronto, Toronto, Ontario, Canada.

DESIGN: Retrospective evaluation of treatment modality.

METHODS: This study consisted of a detailed review of the history, drugs, and methods of intracameral prophylaxis and microbiological and pharmacodynamics analysis of options. A review of potential drug sources and doses was performed and 1 drug, dose, and administration protocol was selected. The current method's adoption reasons are described followed by the authors' experience.

RESULTS: A single infection in 3430 cases occurred with a moxifloxacin-resistant strain of *Staphylococcus epidermidis* when moxifloxacin 100 mcg in 0.1 mL was used. Increasing the dose and changing the administration technique resulted in no infections in 4601 cases and no detrimental side effects or complications.

CONCLUSION: Intracameral moxifloxacin prepared by dilution of 3 cc moxifloxacin 0.5% (Vigamox) with 7 cc balanced salt solution and with the administration of 0.3 to 0.4 cc (450 to 600 mcg.) as the final step in cataract surgery via the side port after the main incision has been sealed and hydrated showed advantages over alternative intracameral antibiotic prophylactic methods, with minimum risk.

Financial Disclosure: Neither author has a financial or proprietary interest in any material or method mentioned.

J Cataract Refract Surg 2016; 42:1730–1741 © 2016 ASCRS and ESCRS



Supplemental material available at www.jcrsjournal.org.

Postoperative endophthalmitis after cataract surgery is an infrequent (generally estimated at about 1:1000 cases globally) but potentially devastating complication that leads to permanent severe vision loss in about one third of cases.¹ Perioperative antibiotics have been a common mainstay of postoperative endophthalmitis prophylaxis for decades. Despite the fact that clinical outcome studies have not affirmed a definite protective effect of postoperative topical antibiotics in endophthalmitis prophylaxis, the most recent American Society of Cataract and Refractive Surgery (ASCRS) and European Society of Cataract and

Refractive Surgeons (ESCRS) surveys indicate that nearly all surgeons prescribe topical antibiotics after cataract surgery.^{2–7}

Multiple studies suggest that the route of antibiotic delivery might be critical in determining efficacy.¹ In a landmark study,⁸ the ESCRS performed a large prospective randomized placebo-controlled trial based on the original work of Montan et al.⁹ to evaluate the prophylactic effect of intracameral cefuroxime on the incidence of postoperative endophthalmitis after cataract surgery. It was observed that the risk for endophthalmitis in patients receiving intracameral injections of

cefuroxime at the conclusion of cataract surgery was 5-fold lower and that of culture-proven endophthalmitis was 6-fold lower than those not receiving intracameral cefuroxime. The finding has been reaffirmed by several other studies, using intracameral cephalosporins.^{6,10-19}

Table 1 shows the collected results of published studies comparing cases that received postoperative intracameral cephalosporin prophylaxis with cases that did not. Across the published studies,^{2,6,9-19} the use of intracameral cephalosporins was associated with a reduction in the rate of postoperative endophthalmitis by 80% to 90%. Collectively, the mean values across these studies, weighted by case numbers, were 1 case of postoperative endophthalmitis in 543 cases without administration of intracameral cephalosporins and 1 case of postoperative endophthalmitis in 3294 cases when an intracameral cephalosporin was used. The ratios of risk in the intracameral cephalosporin group and the no intracameral cephalosporin groups were similar in all studies, even comparing very small with very large studies (eg, Romero et al.¹¹ from Reus, Spain, to Lundström et al.¹⁶ from the Swedish National Cataract Registry). The mean risks are reduced by the fact that the last 2 studies included^{18,19} found unusually low risks in both groups. However, a single study of intracameral cefuroxime from the L.V. Prasad Institute in Hyderabad, India²⁰ found only a marginal reduction in the rate of infection but an increased incidence of cefuroxime-resistant gram-negative isolates, which begs further investigation and suggests the question, "Is cefuroxime the best drug for intracameral prophylaxis?"

Since the publication of the ESCRS study, the administration of prophylactic intracameral antibiotics has continually risen in popularity. The ESCRS 2012 survey of members found that 74% of responding ophthalmic surgeons always used intracameral antibiotics.² A 2014 online survey of the ASCRS members also indicated increasing adoption of intracameral antibiotic

prophylaxis compared with a similar survey in 2007 (47% versus 30%), although this was still considerably lower than that found among ESCRS members.^{3,21} Both the 2011 American Academy of Ophthalmology Cataract Preferred Practice Pattern Guidelines²² and a 2011 ASCRS Cataract Clinical Committee review of endophthalmitis prevention²³ reported stronger evidence supporting direct intracameral injection than for any other method of antibiotic prophylaxis.

Although the ESCRS Endophthalmitis Study clearly showed the benefit of intracameral antibiotic prophylaxis with cefuroxime, it only tested 1 antibiotic at 1 concentration, leaving the critical questions open, as suggested by the data from the L.V. Prasad Institute,²⁰ of whether intracameral cefuroxime is the best antibiotic for postoperative endophthalmitis prophylaxis and what the ideal dose is. Cefuroxime, a second-generation cephalosporin approved in the United States in 1978 (Zinacef), was initially chosen for intracameral injection by Montan et al.^{9,24} in the early 1990s, before the availability of fourth-generation fluoroquinolones, including moxifloxacin (Vigamox) and gatifloxacin (Zymar), which have since been shown to be the most effective broad-spectrum topical antibiotics for ophthalmic use.²⁵ At the International Intraocular Implant Club Symposium on postoperative endophthalmitis held at the 20th Congress of the European Ophthalmological Society in Vienna, Austria, June 7, 2015, Anders Behndig presented data from the Swedish National Cataract Surgery Database suggesting that the postoperative endophthalmitis rates after intracameral cefuroxime and moxifloxacin were similar but that postoperative endophthalmitis after cefuroxime resulted in higher rates of visual loss because of the high proportion of cases infected with resistant *Enterobacter* species, thus confirming the finding from the L.V. Prasad Institute²⁰ of an increased incidence of cefuroxime-resistant gram-negative isolates when intracameral cefuroxime is used.

Compared with the earlier generation fluoroquinolones, cephalosporins, and the other candidate drugs for intracameral prophylaxis, moxifloxacin offers potent dose-dependent bactericidal activity against a broader spectrum of key pathogens causing postoperative endophthalmitis.²⁶⁻²⁸ Moxifloxacin is a fourth-generation fluoroquinolone approved for systemic use in the U.S. in 1999 (Avelox) and as topical eyedrops (moxifloxacin 0.5% [Vigamox]) in 2003. It has excellent ocular penetration after topical administration and reduced susceptibility to the emergence of bacterial resistance, which is dose-dependent as opposed to absolute.²⁹⁻³¹

Vancomycin, the third antibiotic commonly used intracamerally for endophthalmitis prophylaxis, was first sold in 1954 and is a unique antibiotic with its

Submitted: July 13, 2016.

Final revision submitted: October 2, 2016.

Accepted: October 2, 2016.

From York Finch Eye Associates, Humber River Hospital and University of Toronto, Toronto, McMaster University (Arshinoff), Hamilton, Ontario, and the Department of Ophthalmology (Modabber), McGill University, Montreal, Quebec, Canada.

Presented in part at the ASCRS Symposium on Cataract, IOL and Refractive Surgery, New Orleans, Louisiana, USA, May 2016.

Corresponding author: Steve A. Arshinoff, MD, FRCSC, York Finch Eye Associates, 2115 Finch Avenue West, Number 316, Toronto, Ontario M3N 2V6, Canada. E-mail: ifix2is@gmail.com.

Table 1. Published results of intracameral prophylaxis with cephalosporins, with totals, weight averaged by case numbers.

Study*/Location	IC Antibiotic			n	Postoperative Endophthalmitis			
	Type	Dose (mg/mL)	Years		No IC (n)	IC (n)	%	P Value
Barry ² /ESCRS study	Cefuroxime	1.0/0.1	2003–2006	16 603	1/337	1/1621	0.07	<.001
Montan ⁹ /Sweden	Cefuroxime	1.0/0.1	1990–1999	66 200	1/383	1/1600	0.06	<.001
Garat ¹⁰ /Barcelona, Spain	Cefazolin	2.5/0.1	2002–2007	18 579	1/240	1/2130	0.047	<.001
Romero ¹¹ /Reus, Spain	Cefazolin	1.0/0.1	2001–2004	7268	1/160	1/1809	0.055	<.001
Garcia-Saenz ¹² /Madrid, Spain	Cefuroxime	1.0/0.1	1999–2008	13 652	1/169	1/2352	0.043	<.001
Van der Merwe ¹³ /South Africa	Cefuroxime	1.0/0.1	2003–2009	8190	1/184	1/1324	0.08	<.01
Barreau ¹⁴ /France	Cefuroxime	1.0/0.1	2003–2008	6195	1/81	1/2289	0.04	<.001
Wejde ¹⁵ /Sweden NCR	Cefuroxime	1.0/0.1	1999–2001	188 151	1/454	1/1887	0.053	<.001
Lundström ¹⁶ /Sweden NCR	Cefuroxime	1.0/0.1	2002–2004	225 471	1/290	1/2231	0.045	<.001
Friling ⁶ /Sweden NCR	Cefuroxime	1.0/0.1	2005–2010	464 996	1/255	1/3756	0.027	<.001
Shorstein ¹⁷ /California, USA	Cefuroxime	1.0/0.1	2007–2011	16264	1/310	1/3125	0.032	<.001
Arshinoff ¹⁸ /iSBCS	Cefuroxime	1.0/0.1	2010–2011	69 670	1/1987	1/9175	0.011	<.01
Jabbarvand ¹⁹ /Teheran, Iran	Cefuroxime	1.0/0.1	2006–2014	480 112	1/4055	0/25 920	0	<.01
Weight averaged totals	Cephalosporins	—	1990–2014	1 581 421	1/543	1/3294	0.03	<.001

IC = intracameral; iSBCS = International Society of Bilateral Cataract Surgeons; n = number of cases in study; NCR = Swedish National Cataract Registry
*First author

name derived from “vanquished” because it was thought to be the antibiotic to end the need for new antibiotics. It is made by the soil bacterium *Amycolatopsis orientalis* (*Actinometales* order, *Pseudonocardiales* family member) using non-ribosomal cytoplasmic protein synthetases and consists of 7 modified amino acids.^A Vancomycin was initially introduced for intraocular use by Gills in 1991³² and Gimbel et al. in 1994.³³ General use of vancomycin only infrequently leads to bacterial resistance, with the first resistant strains appearing more than 40 years after its initial marketing. Ophthalmic use of antibiotics is believed to be much less likely than systemic use to contribute to selection of resistant bacterial strains.^{34,35} Vancomycin is generally reserved as an agent of last resort and as a consequence, resistant strains, especially staphylococci, have become a huge medical problem in the past 20 years. It is on the World Health Organization's List of Essential Medicines.^A Vancomycin has now been, at least temporarily, removed as a serious candidate for prophylactic intracameral use because of the recent appearance of cases of hemorrhagic occlusive retinal vasculitis as a risk of its use intracamerally.³⁶

PATIENTS AND METHODS

All surgical cases were performed sequentially by the same surgeon (S.A.A.) using clear corneal incisions, with no cases excluded. Intracameral vancomycin was used in the first 4797 cases between January 1996 and November 2004, with no infections occurring. Searching for another drug began because generic vancomycin purchased by Canadian hospitals, beginning in 2004, was found to cause toxic

anterior segment syndrome (TASS). The subsequent 3430 eyes were therefore given 100 mcg moxifloxacin in 0.1 cc balanced salt solution between November 2004 and February 2010, after which the last 4601 eyes received 300 to 600 mcg moxifloxacin in 0.2 to 0.4 cc balanced salt solution between February 2010 and August 2016. All intracameral injections were given at the termination of the surgical procedure, after the main incision was hydrated with a balanced salt solution to ensure that it was sealed. Then, the antibiotic was injected via the side port as the final step in surgery.

All concentrations for antibiotics in the anterior chamber were calculated by dividing the dose injected by the mean approximate volume (because it varies among eyes) of the anterior chamber and capsular bag in the aphakic state as follows: The mean value of the volume of aqueous in the human eye is 0.31 mL (anterior chamber 0.25 mL and posterior chamber 0.06 mL). Studies of the human lens volume have yielded results from 0.16 mL to 0.26 mL, increasing with age, so a middle number of about 0.21 mL was used for a mature adult with an empty capsular bag.^{37,B} Alcon Laboratories^C confirmed that the volume of a typical intraocular lens (IOL) (+22.0 diopter, Acrysof SN60WF) is 14.5 mm³ = 0.0145 mL. Thus, a reasonable estimate of the pseudophakic anterior chamber volume to which an intracameral antibiotic is injected is approximately 0.5 mL (0.31 + 0.21 – 0.015). So, if 500 mcg of an antibiotic were injected into this space, the concentration becomes 500 mcg/0.5 mL = 500 mg/500 mL, or 1 gm/L. The initial anterior chamber concentrations in Figure 1, top, and Figure 2A and were thus calculated.

To assess whether these calculations agree with experimental data, the article of Montan et al.⁹ was reviewed. They injected 1 mg cefuroxime into the anterior chamber at the end of cataract surgery and measured the anterior chamber concentration 30 seconds later to average 2614 mg/mL ± 209 (SD) in 10 patients (but not surprisingly the range varied by a broad factor of 2). The calculation in this study would suggest 2000 mg/mL. The difference can be

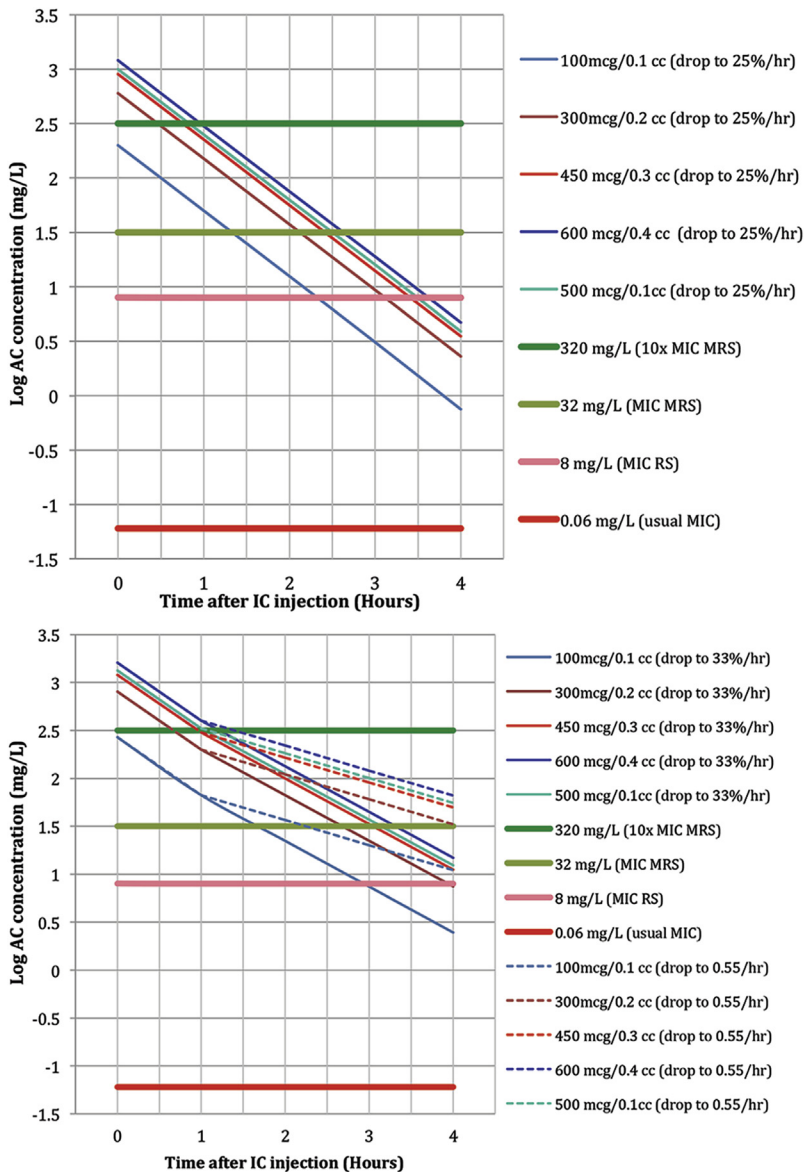


Figure 1. Models of calculated design in aqueous concentration of intracamerally injected moxifloxacin; graphs of data in Figures 2A, 2B, and 2C. *Top:* Calculated time courses of postoperative intracameral moxifloxacin injection protocols, assuming full anterior chamber at injection and 4-fold decline per hour. Log of decline in intracameral levels of moxifloxacin (to obtain straight lines) assuming anterior chamber volume of 0.5 mL at injection and a drop of 50% every 30 minutes. The bottom horizontal red line (0.06 mg/L) represents the usual MIC₉₀ of moxifloxacin versus nonresistant staphylococci. All injection doses (*sloped lines*) are more than 1 log unit above the red line for 4 hours, indicating that they maintain intracameral concentrations more than 10 times the MIC₉₀ for nonresistant staphylococci. However, considering resistant strains of staphylococci, even the highest dose regimens (450, 500, and 600 mcg) retain intracameral concentrations exceeding 10 times the MIC of the most resistant strain of staphylococci ever reported (10× MIC most resistant strain, *bright green horizontal line*) for less than 1 hour after injection, whereas they retain intracameral levels exceeding the MIC of the strain isolated from the study patient (MIC resistant strain, *pink horizontal line*) for almost 3.5 hours postoperatively. This is probably the worst-case scenario for concentration drop of intracameral moxifloxacin in the anterior chamber postoperatively (data values in Figure 2A) *Bottom:* Calculated time courses of postoperative intracameral moxifloxacin injection protocols, assuming decline to 0.33% or 55% per hour after the first hour. Log of decline in intracameral levels of moxifloxacin adjusting initial concentration based on Montan et al.'s⁹ measurements and assuming a 4-fold decline in concentration over the first hour (partially explained by initial volume expansion of the anterior chamber after injection in a soft eye) and subsequently reduced to one third per hour thereafter (*sloped solid lines*). The bottom horizontal dark red line (0.06 mg/L) represents the usual MIC₉₀ of moxifloxacin versus sensitive staphylococci. All dose decline lines remain more than 1 log unit above the red line for 4 hours, indicating they maintain intracameral concentrations more than 10 times the MIC₉₀ for nonresistant staphylococci for more than 4 hours. However, considering resistant

strains of staphylococci, it is apparent that even the highest dose regimens retain intracameral concentrations exceeding 10 times the MIC of the most resistant strain of *Staphylococcus* ever reported (10× MIC most resistant strain, *bright green horizontal line*) for about 1 hour after injection, whereas they retain intracameral levels exceeding the MIC of the strain isolated from the study patient (MIC resistant strain, *pink horizontal line*) for over 4 hours after injection. The 100 mcg injection retains that level for only 3 hours. The dashed lines represent what is likely a more accurate estimate of dilution after the first hour at a rate of drop to 0.55 per hour (the rate is based on the law of exponential decay) but might be a best-case scenario of how long an antibiotic remains in the anterior chamber after intracameral injection. All injection doses but the lowest (100 mcg) retain moxifloxacin levels exceeding the MIC of the most resistant strain (MIC most resistant strain, *pale green horizontal line*) for 4 hours or more. Somewhere between these 2 groups of curves probably reflects reality more accurately than those in Figure 1, *top* (data values in Figures 2A, 2B, and 2C) (IC = intracameral concentrations; MRS = most resistant strain; RS = resistant strain isolated from study patient).

accounted for by the fact that Montan et al.⁹ used silicone IOLs, which have at least double the volume of hydrophobic acrylic IOLs, and preferred to inject the cefuroxime into a soft eye to prevent leakage and therefore into a smaller space than the full anterior chamber calculated here. Considering all of this, the calculations in this seem accurate, admitting that the antibiotic concentrations in the anterior chamber might be approximately 20% higher immediately after

injection than calculated in Figure 1, *top*, and Figure 2A and because the volume is likely less than a fully pressurized anterior chamber. Figure 1, *bottom*, Figure 2B, and Figure 2C begin with anterior chamber concentrations increased from the current calculations by the ratio of Montan et al.'s data⁹ divided by the ratio here (2614/2000) in an attempt to obtain a more realistic estimate of the immediate postoperative anterior chamber antibiotic concentration. The same article

Time Postop	Moxifloxacin Dose									
	100 mcg in 0.1 cc		300 mcg in 0.2 cc		450 mcg in 0.3 cc		600 mcg in 0.4 cc		500 mcg in 0.1 cc	
	AC Concentration (mg/L)	Log	AC Concentration (mg/L)	Log	AC Concentration (mg/L)	Log	AC Concentration (mg/L)	Log	AC Concentration (mg/L)	Log
At injection	200	2.3	600	2.78	900	2.95	1200	3.08	1000	3
At 1 hour	50	1.7	150	2.18	225	2.35	300	2.48	250	2.4
At 2 hours	12.5	1.01	37.5	1.57	56	1.75	75	1.88	62.5	1.8
At 3 hours	3.1	0.49	9.4	0.97	14	1.15	19	1.28	16	1.2
At 4 hours	0.8	-0.12	2.3	0.36	3.5	0.54	4.7	0.67	3.9	0.59
Optimum bactericidal effect (level >320 mg/L)	0.0 hr		0.45 hr		0.75 hr		0.9 hr		0.8 hr	

>10× MIC₉₀ most resistant case (320 mg/L)
 ≥MIC₉₀ most resistant case (32 mg/L)

<MIC₉₀ most resistant case (32 mg/L)
 <MIC₉₀ of our case (32 mg/L)

Figure 2A. Model of calculated decline in aqueous concentration of intracamerally injected moxifloxacin; tabular representation of data in Figure 1, (top). Calculated postoperative intracameral moxifloxacin concentrations after different injection protocols with ongoing concentration drop to 25% per hour (AC = anterior chamber; MIC90 = 90% minimum inhibitory concentration).

also determined, by measurement, a 4-fold drop in cefuroxime concentration over the first hour postoperatively. The authors stated that they expected the drop after the first hour to be slower because the rate of aqueous turnover (2.4 mL/min) is approximately 1.0% of the aqueous volume of the anterior chamber per minute.^{38,B} Yu³⁹ states that aqueous turnover in the healthy eye results in a half-life of most drugs in the anterior chamber of approximately 45 to 60 minutes but can be longer depending on tissue binding. As stated by Montan et al.,⁹ information on this issue is sparse and the rate of drop in aqueous concentration should decline after the first hour because of dilution over the first hour as the eye fills with aqueous, the anterior chamber deepens, and the normal rate of aqueous turnover, which is only approximately 1.0% to 1.5% of aqueous volume per minute. A worst-case scenario was assumed; that is, that the anterior chamber concentration continues to decline by 50% every half hour (Figure 1, top, and Figure 2A).

Also calculated was the decline in anterior chamber moxifloxacin concentration, with more optimistic assumptions used. If the 4-fold decline over the first hour measured by Montan et al.⁹ were a result of dilution and washout and dilution were approximately 20% (above), the washout rate should cause a decline in the concentration to about one third every hour subsequent to the first hour, close to what can be calculated (below) with an aqueous turnover of 1.5% per minute. Figure 1, bottom (solid lines), and Figure 2B show the aqueous concentration assuming a decline to one third per hour after the first hour after a decline to one fourth over the first hour, in an attempt to be more realistic.

For a best-case scenario calculation, the mathematical law of exponential decay was applied.^D If one were to optimistically accept that the aqueous turnover is approximately 1.0% per minute and there are 60 minutes per hour and assume that the antibiotic is equally distributed

Time Postop	Moxifloxacin Dose									
	100 mcg in 0.1 cc		300 mcg in 0.2 cc		450 mcg in 0.3 cc		600 mcg in 0.4 cc		500 mcg in 0.1 cc	
	AC Concentration (mg/L)	Log	AC Concentration (mg/L)	Log	AC Concentration (mg/L)	Log	AC Concentration (mg/L)	Log	AC Concentration (mg/L)	Log
At injection	267	2.43	800	2.9	1200	3.08	1600	3.2	1333	312
At 1 hour	67	1.82	200	2.3	300	2.48	400	2.6	333	2.52
At 2 hours	22.3	1.35	67	1.82	100	2	133	2.12	111	2.05
At 3 hours	7.4	0.87	22.2	1.35	33.3	1.52	44.4	1.65	37	1.57
At 4 hours	2.5	0.39	7.4	0.87	11.1	1.05	14.8	1.17	12.3	1.09
Optimum bactericidal effect (level >320 mg/L)	0.0 hr		40 min		0.95 hr		1.2 hr		1.0	

>10× MIC₉₀ most resistant case (320 mg/L)
 ≥MIC₉₀ most resistant case (32 mg/L)

<MIC₉₀ most resistant case (32 mg/L)
 <MIC₉₀ of our case (32 mg/L)

Figure 2B. Model of calculated decline in aqueous concentration of intracamerally injected moxifloxacin; tabular representation of data in Figure 1, bottom (solid lines). Calculated postoperative intracameral moxifloxacin concentrations after different injection protocols with volume expansion in first hour and concentration drop to 25% followed by concentration drop to 33% per hour thereafter (AC = anterior chamber; MIC90 = 90% minimum inhibitory concentration).

Time Postop	Moxifloxacin Dose									
	100 mcg in 0.1 cc		300 mcg in 0.2 cc		450 mcg in 0.3 cc		600 mcg in 0.4 cc		500 mcg in 0.1 cc	
	AC Concentration (mg/L)	Log	AC Concentration (mg/L)	Log	AC Concentration (mg/L)	Log	AC Concentration (mg/L)	Log	AC Concentration (mg/L)	Log
At injection	267	2.43	800	2.9	1200	3.08	1600	3.2	1333	3.12
At 1 hour	67	1.82	200	2.3	300	2.48	400	2.6	333	2.52
At 2 hours	36.6	1.56	110	2.04	165	2.22	220	2.34	183	2.26
At 3 hours	20.1	1.30	60.2	1.78	90.4	1.96	120	2.08	100	2.0
At 4 hours	11.0	1.04	33.1	1.52	49.6	1.7	66.1	1.82	55.1	1.74
Optimum bactericidal effect (level >320 mg/L)	0.0		0.45		0.75		0.9		0.8	

■ >10× MIC₉₀ most resistant case (320 mg/L) ■ ≥MIC₉₀ most resistant case (32 mg/L)
■ <MIC₉₀ most resistant case (32 mg/L) ■ <MIC₉₀ of our case (32 mg/L)

Figure 2C. Model of calculated decline in aqueous concentration of intracamerally injected moxifloxacin; tabular representation of data in Figure 1, bottom (dashed lines). Calculated postoperative intracameralmoxifloxacin concentrations after different injection protocols with volume expansion in first hour and concentration drop to 25% followed by concentration drop to 55% per hour thereafter (AC = anterior chamber; MIC90 = 90% minimum inhibitory concentration).

in the aqueous (which it is not exactly because flow is somewhat directional), exponential decay can be calculated as follows:

$$N(t) = N_{(0)}e^{-\lambda t}$$

where N is the value at time t and λ is the decay constant (1.0% per minute).

The goal is to determine $N_{(60)}\%$, and take $N_{(0)}\% = 100\%$, so $N_{(60)} = 100e^{-0.01(60)} = 100e^{-0.6} = 54.88\%$ of initial anterior chamber concentration at 1 hour.

If, less optimistically, one were to take aqueous turnover at 1.5% per minute, the calculation yields decline to 40.66% of the starting value, each hour, which is close to the decline to one third above.

To calculate the most optimistic scenario, by the law of exponential decay,¹ the rate of decline of moxifloxacin (or other solute) will be to 55% of the initial value each hour (Figure 1, bottom (dashed lines), and Figure 2C). One should expect that the real clinical rate of decline of antibiotic concentration in the anterior chamber falls somewhere in between Figure 1 and Figures 2A, 2B, and 2C.

Bactericidal assessment of ideal doses of antimicrobial agents can be complicated; however, in general an agent is referred to as bacteriostatic with respect to a given microbial organism if the minimum bactericidal concentration is greater than 4 times the minimum inhibitory concentration (MIC). For fluoroquinolones, bactericidal dose-dependent antibiotics, the rate of bacterial kill increases with progressively higher antibacterial concentrations.⁴⁰ Typically, concentrations are maintained at 2 to 4 times the MIC throughout the dosing interval for antibiotics. The ideal bactericidal effect for concentration-dependent antibiotics, such as moxifloxacin, is obtained at concentrations at least 10 times the MIC of the target organism.⁴¹ Therefore, the achievable concentrations of moxifloxacin with different dosing regimens were determined considering these targets (Figure 1 and Figures 2A, 2B, and 2C) and Figures 2A, 2B, and 2C were color coded to

show the expected bactericidal or static effect of each dosage regimen.

RESULTS

Figure 2A shows the brief time (which is longer than for other drugs) that intracameral moxifloxacin, remains at bactericidal levels, exceeding 10 times the MIC₉₀ (90% MIC) of *Staphylococcal* species. Montan has published that antibiotic concentrations decrease by 50% every half hour in the anterior chamber for the first hour. Figure 2A was calculated by extrapolating this rate of concentration decline to 4 hours for all illustrated injection concentrations. Figure 1, top, shows the data in a graphic format.

Figure 2B reflects the recognition that some of the concentration reduction observed by Montan et al. in the first hour was the result of volume expansion of the anterior chamber. Thus, the decline rate was reduced to decline to one third rather than one fourth each hour after the first hour. In this manner, the calculations in this study seem to yield the most likely rate of decline in concentration after the injection of intracameral moxifloxacin. Figure 1, bottom, shows the data in a graphic format (solid lines).

Figure 2C accepts the decline to one quarter over the first hour but thereafter uses the law of exponential decay rate, yielding declines to 0.55 per hour to calculate concentrations after the first hour. It yields the most optimistic scenario for persistence of the antibiotic in the anterior chamber over time. This is shown in graphic format in Figure 1, bottom (dashed lines).

To choose an optimum administration method, it is apparent that the MIC of this study's postoperative endophthalmitis case was exceeded by the anterior chamber concentration for over 3 hours in all but the 100 mcg injection dose if it is assumed to decline to 25% every hour. Figures 2B and 2C reflect slower concentration decline assumptions. In all cases, the 3 highest injection amounts yielded prolonged efficacy of the injected moxifloxacin dose. The logical choice would be to inject 0.1 cc moxifloxacin from the bottle or an amount somewhere between columns 450 and 600 mcg, which are safer than 500 mcg in 0.1 cc from the bottle because they are more dilute and much easier to administer.

DISCUSSION

It can easily be calculated (law of exponential decay^D) that with the administration of 1 mg of cefuroxime in 0.1 mL at the end of surgery (the ESCRS study dose), the concentration of cefuroxime in the anterior chamber drops below 1 mg/mL by 45 minutes postoperatively, a level insufficient to achieve a 1 log unit kill of β -lactam-sensitive *Staphylococcus aureus* in 3 hours.⁴² Intracameral moxifloxacin, a dose-dependent drug, retains bactericidal levels 10 times the MIC of the most resistant potentially offending pathogens for only a limited time period but, because of its potent dose-dependent activity, even at low injection concentrations, it remains bactericidal for much longer than cefuroxime. Using the dose we arrived at (450 to 600 mcg/0.3 to 0.4 cc), the concentration of moxifloxacin in the anterior chamber at 150 minutes postoperatively can be calculated to exceed 50 mcg/mL, a level sufficient to achieve a bacterial kill of fluoroquinolone resistant *S aureus* exceeding 3 log units in 3 hours.⁴³

Why did we reassess the dose of intracameral moxifloxacin? In 2010, after administering prophylactic intracameral moxifloxacin (100 mcg in 0.1 cc, a lower dose than we currently recommend) to more than 3400 cataract cases, a single case of postoperative endophthalmitis with a moxifloxacin-resistant pathogen occurred in 1 eye of a patient who had immediately sequential bilateral cataract surgery with no complications in both procedures with similar phaco and total surgical times. The most common bacterial cause of endophthalmitis is *Staphylococcal* species bacteria, with the usual MIC₉₀ to moxifloxacin being 0.06 mg/L.⁴⁴ Our patient's eye grew *S epidermidis* with an MIC of 8 mg/L (133 times usual MIC). The highest reported MIC of a staphylococcal strain to moxifloxacin known to us is 32 mg/L (500 times usual MIC).⁴⁵ Although other surgical variables, such as a leaky incision, could have precipitated the infection, the unusually high MIC₉₀ of the infecting organism

prompted a reassessment of our administration protocol, dose recalculation, and reevaluation of the elimination pattern of intracameral moxifloxacin. The data reproduced herein convincingly suggested a change in our dosage and administration protocol and was the impetus for our current practice and this paper.

Regarding why we inject 0.1 cc in the anterior chamber, historically, cataract surgeons did not inject antibiotics and only rarely other pharmacologic agents specifically supplied for intraocular use (eg, acetylcholine chloride [Miochol] and carbachol [Miostat]) into the anterior chamber. We administered drugs topically and sometimes subconjunctivally. We inherited the idea of intraocular antibiotic injections from our retina colleagues, who initially injected antibiotics intravitreally to treat endophthalmitis. They appropriately chose to use 0.1 cc per injection because the intravitreal space is very limited. As a consequence of adoption of this practice, intracameral antibiotics have also been injected into the anterior chamber in aliquots of 0.1 cc. Does this really make sense for anterior segment surgery?

It is difficult to inject exactly 0.1 cc into the anterior chamber via the main cataract incision and less so, but still very challenging, via the side port at the termination of surgery. In general, we do not have available syringes to use that are smaller than the common 1.0 cc tuberculin (TB) syringes. An amount of 0.1 cc is a very small volume in these syringes, and attempts to administer 0.1 cc are usually only approximate due to fluid and air in the needle and its junction with the syringe, difficulty drawing up and administering exactly 0.1 cc without an interfering small bubble, some loss at the incision site, and incomplete emptying of the syringe during injection. Our estimate, based on experience with thousands of cases, is that we generally inject 0.1 cc \pm 20%, and we believe that a lot of the variation in Montan et al.'s series⁹ was the result of this. We need a better system, at least one in which the \pm 20% is less critical to patient welfare.

It is much easier and more accurate to simply dilute the intracameral antibiotic and plan to replace most of the anterior chamber volume with a 0.3 to 0.4 cc injection, exchanging the anterior chamber volume and sealing the incisions with an injected diluted antibiotic solution, than to inject exactly 0.1 cc through the side port. Given that the surgeon will likely not completely replace all of the aqueous in an eye containing an IOL and that the final pressure of the eye when the surgeon removes the cannula from the side port will vary slightly, it is reasonable to expect that between 0.3 cc and 0.4 cc of aqueous will be replaced (approximately 75%) by the proposed simple washing out of the anterior chamber via the side port. A variation of this

method is common in Japan.⁴⁶ This is best done once the main incision has been hydrated and sealed. Furthermore, lowering the concentration of the antibiotic allows us to make the solution more physiologic by diluting it with a balanced salt solution, thereby reducing potential toxicity to delicate intraocular structures that might be caused by factors such as a high concentration of antibiotic in the injected fluid, excipients, a nonphysiologic pH, and osmolality.

Systemic moxifloxacin use has been reported by Knape et al.⁴⁷ to cause acute iritis and subsequent bilateral iris transillumination, and a suspected single similar iritis case was recently reported by Runde^E when undiluted intracameral moxifloxacin was injected into the vitreous space. However, it has never been reported with intracameral administration into the anterior chamber. It is likely the transport of high moxifloxacin concentrations through the iris tissue and the high concentration obtained in the vitreous by prolonged systemic or intravitreal injection of undiluted moxifloxacin that causes this “toxi-moxi” syndrome reported by Knape et al.⁴⁷ Administration of a larger volume of lower concentration moxifloxacin into the anterior chamber via the side port as the final step of surgery has never been associated with reported toxic effects.

So how to best calculate the effective dose to administer: Once we know the MIC₉₀ of the most likely pathogens we are targeting (staphylococci) and know from the work of Montan et al.⁹ that the concentration of moxifloxacin (or any other solute) will decrease to 25% over the first hour, it is reasonably simple to create tables and graphs showing the relative efficacy of potential choices for intracameral moxifloxacin administration and to choose the most appropriate dose to inject and method to use.

Moxifloxacin eyedrops first became available in 2003 as Vigamox, which is a self-preserved ophthalmic topical formulation without added preservative, containing only sodium chloride, boric acid, and purified water as excipients, in addition to moxifloxacin hydrochloride. Since 2010, another ophthalmic topical preparation, Moxeza, became available, which additionally contains the excipients xanthum gum, sorbitol, and tyloxapol, which has detergent and mucolytic properties and enables reduction of the recommended frequency of topical drop application from 3 times a day (Vigamox) to 2 times a day (Moxeza). Moxeza, likely because of its additional excipients, has been reported to have caused TASS in 12 patients who received intracameral injections.^{48,F} Avelox, injectable moxifloxacin, was approved by the U.S. Food and Drug Administration in 1999.⁴⁹ Its concentration of 1.6 mg/mL (400 mg in 250 mL) might make it seem ideal for injection as an already diluted moxifloxacin solution, close to our

chosen dilution level. However, its pH is 4.1 to 4.6, which makes it unsafe for intracameral injection into the eye.

In India and other countries outside Europe and the U.S., specific intracameral preparations of moxifloxacin have been available since 2013, or earlier, including Auromox 0.5% single-use 1 cc vials and 4-Quin PFS 0.5% single-use prefilled syringes. Injection of 0.1 cc containing 500 mcg of either of these 2 single-use Indian preparations will achieve a concentration in the anterior chamber exceeding 1 mg/mL, very close to what is achieved by our preferred method below. Neither single-use product has been approved for sale in Europe, Canada, or the U.S. In comparison, prediluted cefuroxime (50 mg vials containing 1 mg/0.1 cc, after reconstitution) has been available in Europe (Aprokam) since 2012.

Extensive safety testing using *in vitro* and animal models combined with the results of post-marketing human clinical experience attest to the safety of topical administration of moxifloxacin (Vigamox preparation).^{28,50-54} Moreover, because of its preservative-free formulation, Vigamox is the only available topical fourth-generation fluoroquinolone that has been shown to be safe for intracameral administration.^{22,55-58,G} None of the numerous generic moxifloxacin eyedrops that have recently begun to appear on world markets has been shown to be safe for this use. Furthermore, the commercial availability of moxifloxacin as a self-preserved easily dilutable ophthalmic formulation (Vigamox) removes concerns about dilution errors that have been reported with the more complex dilution procedures required for cefuroxime and vancomycin.^{59,60} Thus, based on its favorable potency, safety, and other issues discussed below, moxifloxacin might be an alternative as an intracameral antibiotic for endophthalmitis prophylaxis.

The revised protocol for the preparation and use of Vigamox we arrived at and has now been used by us in over 4600 cases for intracameral prophylactic moxifloxacin administration ([Appendix 1](#), available at <http://jcrsjournal.org>) consists of mixing an entire bottle (3 cc) of Vigamox with 7 cc of a balanced salt solution in a 12 cc syringe, yielding a concentration of 150 µg/0.1 cc. The circulating nurse then injects 0.8 cc into a small sterile cup on each scrub table, and approximately 0.6 cc of this mixture is aspirated into a 1.0 mL TB syringe. A 27-gauge hockey stick blunt cannula is then attached to the TB syringe and approximately 0.1 mL expelled to make sure all air has been cleared. The scrub nurse then hands the TB syringe to the surgeon. The surgeon inserts the cannula through the side port into the anterior chamber, after the main incision has been sealed and hydrated with a balanced salt solution, and

then injects the diluted Vigamox just under the distal capsulorhexis edge into the capsular bag circulating around the IOL and continues to inject as the cannula is withdrawn, ensuring pressurization of the anterior chamber. The injected Vigamox (0.3 to 0.4 mL containing 450 to 600 µg moxifloxacin) is intended to be sufficient to exchange approximately 75% of the anterior chamber contents, assuming that a small amount will be lost during the injection procedure, yielding a concentration exceeding 1 mg/L (or slightly higher) in the anterior chamber. The surgeon then uses the remaining Vigamox in the syringe to hydrate the side-port incision, during which one can ensure that the anterior chamber has been adequately pressurized. To date, using our revised protocol after our 1 case of postoperative endophthalmitis with the lower dose, no cases of endophthalmitis have been observed and we have not observed a single case of postoperative anterior chamber fibrin, significant iritis, or other toxic side effects of intracameral moxifloxacin administration.

Despite our adoption of intracameral Vigamox, we have continued to give our patients topical Vigamox postoperatively 6 times per day for the first 3 days, then 4 times a day until the bottle is empty, which is usually about 1 week. We have persisted with topical Vigamox at the same frequency as topical steroids and nonsteroidal antiinflammatory drugs, despite intracameral use, because all our colleagues use postoperative topical antibiotics, while only some have adopted intracameral injections, making postoperative topical antibiotics the expected standard of care for us.

In summary, our experience with intracameral moxifloxacin, spanning more than 8000 cases since November 2003, has been very encouraging. The senior author was the first in the world to use and advocate the use of Vigamox for intracameral antibacterial prophylaxis at the end of cataract surgery. We have seen no deleterious side effects from its administration but did have to increase the initial dose, reassess all parameters of antibiotic use intracamerally, and refine the administration technique after our 1 endophthalmitis case—an infection with a moxifloxacin-resistant strain of *S epidermidis* in January 2010.

Many centers have also published excellent results using prophylactic intracameral moxifloxacin.^{17,61,62} We believe that intracameral Vigamox offers multiple advantages, including easy availability, low cost (about US \$1 to US \$2 per case in Canada), and simple dilution without the need for nitrocellulose membrane air filters (Millipore filters). Furthermore, its yellow color makes the syringe easily identifiable.

Finally, we must perform a failure analysis, because everything sometimes fails. If an infection

occurs after using intracameral Vigamox, it will likely be caused by moxifloxacin-resistant staphylococci, which are generally very sensitive to the usual endophthalmitis protocol of vancomycin and ceftazidime because the mechanism of the antibacterial action of moxifloxacin is completely different from those of the drugs we generally use to treat endophthalmitis, making cross resistance less likely. Infections that occur with intracameral cefuroxime are frequently caused by destructive resistant bacteria, such as *Enterobacter*. This might be because cefuroxime is in the same family of antibiotics as ceftazidime and its mechanism of antibacterial action is similar to those of the preferred agents used to treat endophthalmitis (vancomycin and ceftazidime [all inhibit cell wall synthesis]), resulting in the failed cases often being infected with *Enterobacter* and the resultant outcome all too often being blindness.

Our study has limitations because it was an analysis of sequential patients, 80% of whom had immediately sequential bilateral cataract surgery. It was not a randomized controlled trial and did not contain sufficient patients to definitively prove superiority of 1 drug over the others. Intracameral prophylaxis in cataract surgery is an ongoing story. We hope that new, better drugs will become available because new cases of bacterial resistance will inevitably arise. Adherence to quality methodology in studies of pharmacodynamics and microbiology should permit us to stay 1 step ahead of the bacteria that threaten our patients.

WHAT WAS KNOWN

- Intracameral antibiotics are known to significantly reduce the rate of post-cataract surgery endophthalmitis. Cefuroxime, moxifloxacin, and vancomycin are the 3 most commonly used antibiotics intracamerally. Cefuroxime is strongly promoted by ESCRS and is most commonly used in Europe. Moxifloxacin is probably the most commonly used antibiotic for this outside Europe. Vancomycin was the first drug used for intracameral antibiotic prophylaxis; however, recent concern about it has arisen because of associated hemorrhagic occlusive retinal vasculitis.

WHAT THIS PAPER ADDS

- Intracameral moxifloxacin prepared by dilution of 3 cc moxifloxacin 0.5% with 7 cc balanced salt solution and with the administration of 0.3 to 0.4 cc (450 to 600 mcg.) as the final step in cataract surgery via the side port after the main incision has been sealed and hydrated showed advantages over alternative intracameral antibiotic prophylactic methods, with minimum risk.

REFERENCES

- Gower EW, Lindsley K, Nanji AA, Leyngold I, McDonnell PJ. Perioperative antibiotics for prevention of acute endophthalmitis after cataract surgery. *Cochrane Database Syst Rev* 2013; (7):CD006364. Available at: <http://onlinelibrary.wiley.com/doi/10.1002/14651858.CD006364.pub2/epdf>. Accessed October 14, 2016
- Barry P. Adoption of intracameral antibiotic prophylaxis of endophthalmitis following cataract surgery; update on the ESCRS Endophthalmitis Study. *J Cataract Refract Surg* 2014; 40:138–142
- Chang DF, Braga-Mele R, Henderson BA, Mamalis N, Vasavada A, for the ASCRS Cataract Clinical Committee. Antibiotic prophylaxis of postoperative endophthalmitis after cataract surgery: results of the 2014 ASCRS member survey. *J Cataract Refract Surg* 2015; 41:1300–1305. Available at: <http://www.ascrs.org/sites/default/files/resources/endophthalmitis-survey-Chang.pdf>. Accessed October 14, 2016
- ESCRS Endophthalmitis Study Group. Prophylaxis of postoperative endophthalmitis following cataract surgery: results of the ESCRS multicenter study and identification of risk factors. *J Cataract Refract Surg* 2007; 33:978–988
- Kessel L, Flesner P, Andresen J, Erngaard D, Tendal B, Hjortdal J. Antibiotic prevention of postcataract endophthalmitis: a systematic review and meta-analysis. *Acta Ophthalmol* 2015; 93:303–317. Available at: <http://onlinelibrary.wiley.com/doi/10.1111/aos.12684/pdf>. Accessed October 14, 2016
- Friling E, Lundström M, Stenevi U, Montan P. Six-year incidence of endophthalmitis after cataract surgery: Swedish national study. *J Cataract Refract Surg* 2013; 39:15–21
- Ong-Tone L. Aqueous humor penetration of gatifloxacin and moxifloxacin eyedrops given by different methods before cataract surgery. *J Cataract Refract Surg* 2007; 33:59–62
- Barry P, Seal DV, Gettinby G, Lees F, Peterson M, Revie CW, for the ESCRS Endophthalmitis Study Group. ESCRS study of prophylaxis of postoperative endophthalmitis after cataract surgery; preliminary report of principal results from a European multicenter study. *J Cataract Refract Surg* 2006; 32:407–410; erratum, 709
- Montan PG, Wejde G, Setterquist H, Rylander M, Zetterström C. Prophylactic intracameral cefuroxime; evaluation of safety and kinetics in cataract surgery. *J Cataract Refract Surg* 2002; 28:982–987
- Garat M, Moser CL, Moser CL, Martín-Baranera M, Alonso-Tarrés C, Álvarez-Rubio L. Prophylactic intracameral cefazolin after cataract surgery; endophthalmitis risk reduction and safety results in a 6-year study. *J Cataract Refract Surg* 2009; 35:637–642
- Romero P, Méndez I, Salvat M, Fernández J, Almena M. Intracameral cefazolin as prophylaxis against endophthalmitis in cataract surgery. *J Cataract Refract Surg* 2006; 32:438–441
- García-Sáenz MC, Arias-Puente A, Rodríguez-Caravaca G, Bañuelos JB. Effectiveness of intracameral cefuroxime in preventing endophthalmitis after cataract surgery; ten-year comparative study. *J Cataract Refract Surg* 2010; 36:203–207
- van der Merwe J, Mustak H, Cook C. Endophthalmitis prophylaxis with intracameral cefuroxime in South Africa. *J Cataract Refract Surg* 2012; 38:2054
- Barreau G, Mounier M, Marin B, Adenis J-P, Robert P-Y. Intracameral cefuroxime injection at the end of cataract surgery to reduce the incidence of endophthalmitis: French study. *J Cataract Refract Surg* 2012; 38:1370–1375
- Wejde G, Montan P, Lundström M, Stenevi U, Thorburn W. Endophthalmitis following cataract surgery in Sweden: national prospective survey 1999–2001. *Acta Ophthalmol Scand* 2005; 83:7–10. Available at: <http://www3.interscience.wiley.com/cgi-bin/fulltext/120092610/PDFSTART>. Accessed October 14, 2016
- Lundström M, Wejde G, Stenevi U, Thorburn W, Montan P. Endophthalmitis after cataract surgery; a nationwide prospective study evaluating incidence in relation to incision type and location. *Ophthalmology* 2007; 114:866–870
- Shorstein NH, Winthrop KL, Herrinton LJ. Decreased postoperative endophthalmitis rate after institution of intracameral antibiotics in a Northern California eye department. *J Cataract Refract Surg* 2013; 39:8–14
- Arshinoff SA, Bastianelli PA. Incidence of postoperative endophthalmitis after immediate sequential bilateral cataract surgery. *J Cataract Refract Surg* 2011; 37:2105–2114
- Jabbarvand M, Hashemian H, Khodaparast M, Jouhari M, Tabatabaei A, Rezaei S. Endophthalmitis occurring after cataract surgery; outcomes of more than 480,000 cataract surgeries, epidemiologic features, and risk factors. *Ophthalmology* 2016; 123:295–301
- Sharma S, Sahu SK, Dhillon V, Das S, Rath S. Reevaluating intracameral cefuroxime as a prophylaxis against endophthalmitis after cataract surgery in India. *J Cataract Refract Surg* 2015; 41:393–399
- Chang DF, Braga-Mele R, Mamalis N, Masket S, Miller KM, Nichamin LD, Packard RB, Packer M, for the ASCRS Cataract Clinical Committee. Prophylaxis of postoperative endophthalmitis after cataract surgery; results of the 2007 ASCRS member survey. *J Cataract Refract Surg* 2007; 33:1801–1805. Available at: http://www.changcataract.com/pdfs/5_Endophthalmitis_10_07.pdf. Accessed October 14, 2016
- American Academy of Ophthalmology. *Cataract in the Adult Eye; Preferred Practice Pattern®*. San Francisco, CA, American Academy of Ophthalmology, 2011. Available at: <http://www.aao.org/asset.axd?id=8d66318f-ff50-408e-9bb1-73d277cf14ce>. Accessed October 14, 2016
- Packer M, Chang DF, Dewey SH, Little BC, Mamalis N, Oetting TA, Talley-Rostov A, Yoo SH, for the ASCRS Cataract Clinical Committee. Prevention, diagnosis, and management of acute postoperative bacterial endophthalmitis. *J Cataract Refract Surg* 2011; 37:1699–1714. Available at: <http://ascrs.org/sites/default/files/resources/endophthalmitis.pdf>. Accessed October 14, 2016
- Montan PG, Wejde G, Koranyi G, Rylander M. Prophylactic intracameral cefuroxime; efficacy in preventing endophthalmitis after cataract surgery. *J Cataract Refract Surg* 2002; 28:977–981
- Mah FS. Fourth-generation fluoroquinolones: new topical agents in the war on ocular bacterial infections. *Curr Opin Ophthalmol* 2004; 15:316–320
- Mather R, Karenchak LM, Romanowski EG, Kowalski RP. Fourth generation fluoroquinolones: new weapons in the arsenal of ophthalmic antibiotics. *Am J Ophthalmol* 2002; 133:463–466
- Kowalski RP, Dhaliwal DK, Karenchak LM, Romanowski EG, Mah FS, Ritterband DC, Gordon YJ. Gatifloxacin and moxifloxacin: an in vitro susceptibility comparison to levofloxacin, ciprofloxacin, and ofloxacin using bacterial keratitis isolates. *Am J Ophthalmol* 2003; 136:500–505
- Bauernfeind A. Comparison of the antibacterial activities of the quinolones Bay 12-8039, gatifloxacin (AM 1155), trovafloxacin, ciprofloxacin, levofloxacin and ciprofloxacin. *J Antimicrob Chemother* 1997; 40:639–651. Available at: <http://jac.oxfordjournals.org/content/40/5/639.full.pdf>. Accessed October 14, 2016
- Wagner RS, Abelson MB, Shapiro A, Torkildsen G. Evaluation of moxifloxacin, ciprofloxacin, gatifloxacin, ofloxacin, and

- levofloxacin concentrations in human conjunctival tissue [letter]. *Arch Ophthalmol* 2005; 123:1282–1283
30. Hwang DG. Fluoroquinolone resistance in ophthalmology and the potential role for newer ophthalmic fluoroquinolones. *Surv Ophthalmol* 2004; 49(suppl 2):S79–S83
 31. Kim DH, Stark WJ, O'Brien TP, Dick JD. Aqueous penetration and biological activity of moxifloxacin 0.5% ophthalmic solution and gatifloxacin 0.3% solution in cataract surgery patients. *Ophthalmology* 2005; 112:1992–1996
 32. Gills J. Filters and antibiotics in irrigating solution for cataract surgery [letter]. *J Cataract Refract Surg* 1991; 17:385
 33. Gimbel HV, Sun R, DeBrof. Prophylactic intracameral antibiotics during cataract surgery: the incidence of endophthalmitis and corneal endothelial cell loss. *Eur J Implant Refract Surg* 1994; 6:280–285
 34. Gordon YJ. Vancomycin prophylaxis and emerging resistance: are ophthalmologists the villains? The heros? *Am J Ophthalmol* 2001; 131:371–376
 35. Ophthalmic moxifloxacin (Vigamox) and gatifloxacin (Zymar). *Med Lett Drugs Ther* 2004; 46:25–27
 36. Witkin AJ, Shah AR, Engstrom RE, Kron-Gray MM, Baumal CR, Johnson MW, Witkin DI, Leung J, Albin TA, Moshfeghi AA, Batlle IR, Sobrin L, Elliott D. Postoperative hemorrhagic occlusive retinal vasculitis; expanding the clinical spectrum and possible association with vancomycin. *Ophthalmology* 2015; 122:1438–1451
 37. Hermans EA, Pouwels PJW, Dubbelman M, Kuijer JPA, van der Heijde RGL, Heethaar RM. Constant volume of the human lens and decrease in surface area of the capsular bag during accommodation: an MRI and Scheimpflug study. *Invest Ophthalmol Vis Sci* 2009; 50:281–289; erratum, 2625. Available at: <http://iovs.arvojournals.org/article.aspx?articleid=2125714>. Erratum Available at: <http://iovs.arvojournals.org/article.aspx?articleid=2126946>. Accessed October 14, 2016
 38. Goel M, Picciani RG, Lee RK, Bhattacharya SK. Aqueous humor dynamics: a review. *Open Ophthalmol J* 2010; 4:52–59. Available at: <https://www.ncbi.nlm.nih.gov/pmc/articles/PMC3032230/pdf/TOOPHTJ-4-52.pdf>. Accessed October 14, 2016
 39. Yu D. Pharmacokinetics in ocular drug development. In: Bonate PL, Howard DR, eds, *Pharmacokinetics in Drug Development: Volume 2: Regulatory and Development Paradigms*. Arlington, VA, American Association of Pharmaceutical Scientists Press, 2004; 391
 40. Pankey GA, Sabath LD. Clinical relevance of bacteriostatic versus bactericidal mechanisms of action in the treatment of gram-positive bacterial infections. *Clin Infect Dis* 2004; 38:864–870. Available at: [http://cid.oxfordjournals.org/conttent/38/6/864.full.pdf](http://cid.oxfordjournals.org/content/38/6/864.full.pdf). Accessed October 14, 2016
 41. Lehman LS. Which antibiotics are time- or concentration-dependent? *Medscape Pharmacotherapy* October 24, 2007
 42. Stratton CW, Liu C, Weeks LS. Activity of LY146032 compared with that of methicillin, ceftazidime, cefuroxime, ciprofloxacin, and vancomycin against staphylococci as determined by kill-kinetic studies. *Antimicrob Agents Chemother* 1987; 31:1210–1215
 43. O'Brien TP, Arshinoff SA, Mah FS. Perspectives on antibiotics for postoperative endophthalmitis prophylaxis: potential role of moxifloxacin. *J Cataract Refract Surg* 2007; 33:1790–1800
 44. Balzi CL, Caballero AR, Tang A, Weeks AC, O'Callaghan RJ. Penetration and effectiveness of prophylactic fluoroquinolones in experimental methicillin-sensitive or methicillin-resistant *Staphylococcus aureus* anterior chamber infections. *J Cataract Refract Surg* 2010; 36:2160–2167
 45. Miller D, Flynn PM, Scott IU, Alfonso EC, Flynn HF Jr. In vitro fluoroquinolone resistance in staphylococcal endophthalmitis isolates. *Arch Ophthalmol* 2006; 124:479–483
 46. Matsuura K, Suto C, Akura J, Inoue Y. Bag and chamber flushing: a new method of using intracameral moxifloxacin to irrigate the anterior chamber and the area behind the intraocular lens. *Graefes Arch Clin Exp Ophthalmol* 2013; 251:81–87
 47. Knape RM, Sayyad FE, Davis JL. Moxifloxacin and bilateral acute iris transillumination. *J Ophthalmic Inflamm Infection* 2013; 3:10. Available at: <https://www.ncbi.nlm.nih.gov/pmc/articles/PMC3605082/pdf/1869-5760-3-10.pdf>. Accessed October 14, 2016
 48. Braga-Mele R, Chang DF, Henderson BA, Mamalis N, Talley-Rostov A, Vasavada A, for the ASCRS Clinical Cataract Committee. Intracameral antibiotics: safety, efficacy, and preparation. *J Cataract Refract Surg* 2014; 40:2134–2142. Available at: http://www.ascrs.org/sites/default/files/resources/JCRS_December_2014.pdf. Accessed October 14, 2016
 49. Caeiro JP, Iannini PB. Moxifloxacin (Avelox®): a novel fluoroquinolone with a broad spectrum of activity. *Expert Rev Anti Infect Ther* 2003; 1:363–370
 50. Donaldson KE, Marangon FB, Schatz L, Venkatraman AS, Alfonso EC. The effect of moxifloxacin on the normal human cornea. *Curr Med Res Opin* 2006; 22:2073–2080
 51. Kowalski RP, Romanowski EG, Mah FS, Yates KA, Gordon YJ. Topical prophylaxis with moxifloxacin prevents endophthalmitis in a rabbit model. *Am J Ophthalmol* 2004; 138:33–37
 52. Kowalski RP, Romanowski EG, Mah FS, Yates KA, Gordon YJ. Intracameral Vigamox® (moxifloxacin 0.5%) is non-toxic and effective in preventing endophthalmitis in a rabbit model. *Am J Ophthalmol* 2005; 140:497–504
 53. Gao H, Pennesi ME, Qiao X, Iyer MN, Wu SM, Holz ER, Meiler WF. Intravitreal moxifloxacin: Retinal safety study with electroretinography and histopathology in animal models. *Invest Ophthalmol Vis Sci* 2006; 47:1606–1611. Available at: <http://iovs.arvojournals.org/article.aspx?articleid=2202874>. Accessed October 14, 2016
 54. Burka JM, Bower KS, VanRoekel C, Stutzman RD, Kuzmowych CP, Howard RS. The effect of fourth-generation fluoroquinolones gatifloxacin and moxifloxacin on epithelial healing following photorefractive keratectomy. *Am J Ophthalmol* 2005; 140:83–87
 55. In brief: hypo- and hyperglycemia with gatifloxacin (Tequin). *Med Lett Drugs Ther* 2006; 48:24
 56. Lane SS, Osher RH, Masket S, Belani S. Evaluation of the safety of prophylactic intracameral moxifloxacin in cataract surgery. *J Cataract Refract Surg* 2008; 34:1451–1459
 57. Espiritu CRG, Caparas VL, Bolinao JG. Safety of prophylactic intracameral moxifloxacin 0.5% ophthalmic solution in cataract surgery patients. *J Cataract Refract Surg* 2007; 33:63–68
 58. Arbisser LB. Safety of intracameral moxifloxacin for prophylaxis of endophthalmitis after cataract surgery. *J Cataract Refract Surg* 2008; 34:1114–1120
 59. Pärssinen O. Ocular toxicity in cataract surgery because of inaccurate preparation and erroneous use of 50mg/ml intracameral cefuroxime [letter]. *Acta Ophthalmol* 2012; 90:e153–e154. Available at: <http://onlinelibrary.wiley.com/doi/10.1111/j.1755-3768.2010.02103.x/pdf>. Accessed October 14, 2016

60. Fry LL. Vancomycin dilution error. *J Cataract Refract Surg* 2005; 31:1674
61. Haripriya A, Chang DF, Namburar S, Smita A, Ravindran RD. Efficacy of intracameral moxifloxacin endophthalmitis prophylaxis at Aravind Eye Hospital. *Ophthalmology* 2016; 123:302–308
62. Matsuura K, Miyoshi T, Suto C, Akura J, Inoue Y. Efficacy and safety of prophylactic intracameral moxifloxacin injection in Japan. *J Cataract Refract Surg* 2013; 39:1702–1706
- E. Runde M. Intracameral moxi causing PDS. *ASCRS Cataract/Refractive Eye Connections Digest*, April 13, 2016
- F. Mamalis N. ASCRS Alert: TASS associated with intracameral antibiotic injection. *ASCRS This Week*, May 8, 2013
- G. Donnenfeld ED, Snyder RW, Kanellopoulos AJ, Perry HD, Cheng C, Wittpenn J, Roberts C, “Safety of Prophylactic Intracameral Gatifloxacin in Cataract Surgery,” presented at the annual meeting of the Ocular Microbiology and Immunology Group, Anaheim, California, USA, November 2003. Available at: <http://eyemicrobiology.upmc.com/2003Abstracts/2003Abs24.htm>. Accessed October 14, 2016

OTHER CITED MATERIAL

- A. Wikipedia; The Free Encyclopedia. Vancomycin. Available at: <https://en.wikipedia.org/wiki/Vancomycin>. Accessed October 14, 2016
- B. Roy S. Normal values in ophthalmology. *Ophthalmology; The resources you need*. Available at: <http://documents.mx/documents/normal-values-in-ophthalmologywall-hanger.html>. Accessed October 14, 2016
- C. Alcon Laboratories, personal communication, May 20, 2016
- D. Wolfram MathWorld. Exponential decay. Available at <http://mathworld.wolfram.com/ExponentialDecay.html>. Accessed October 14, 2016



First author:

Steve A. Arshinoff, MD, FRCSC

*York Finch Eye Associates, Toronto,
Ontario, Canada*