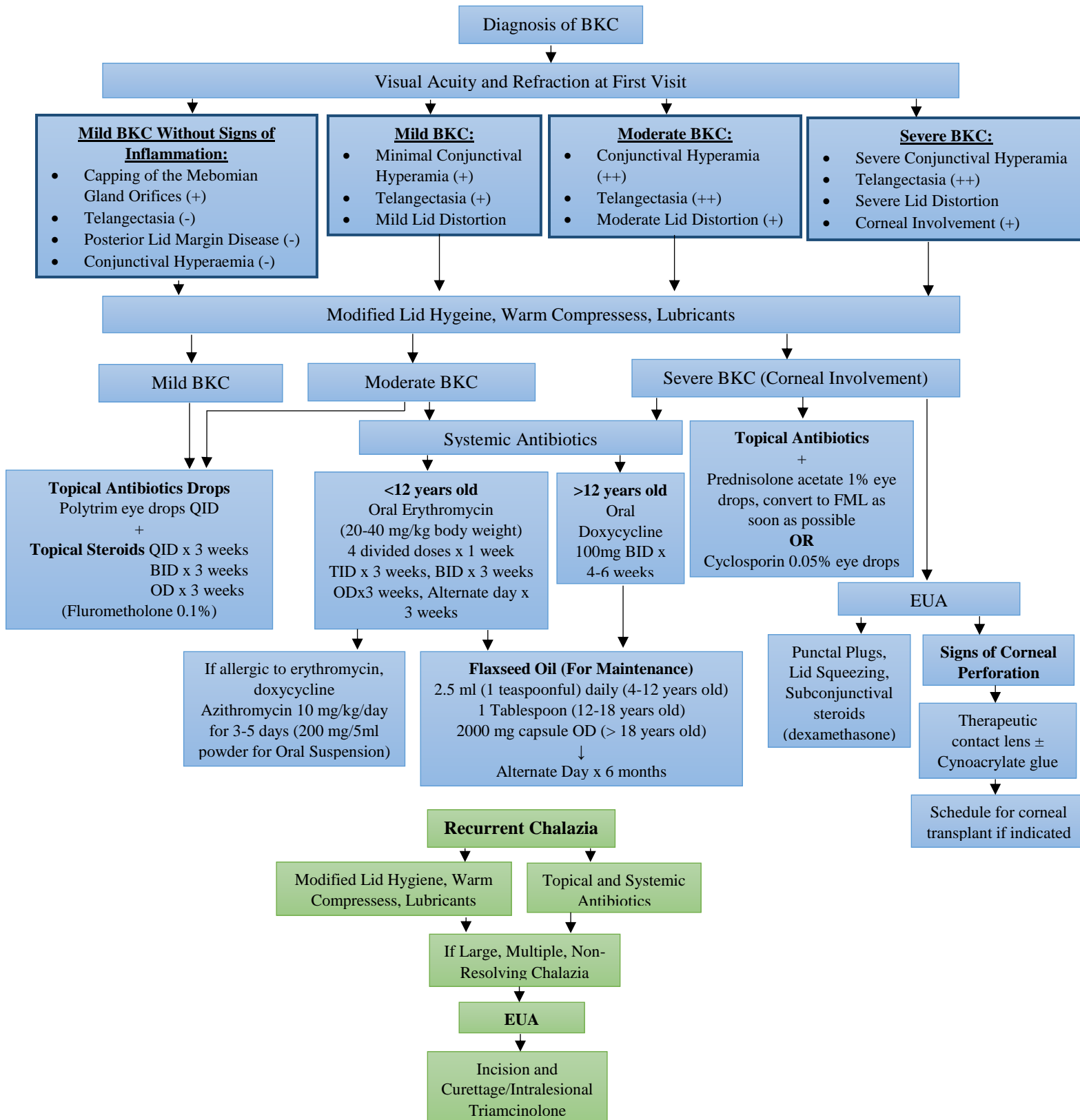


Blepharokeratoconjunctivitis (BKC) Protocol



References:

1. Jones, SM, et al. Visual Outcome and Corneal Changes in Children with Chronic Blepharokeratoconjunctivitis. *Ophthalmology* 2007; 114:2271-2280
2. Hammersmith KM, et al. Blepharokeratoconjunctivitis in Children. *Arch. Ophthalmol.* 2005; 123:167-1670
3. Teo L, Mehta JS, Htoon HM, Tan DT. Severity of Pediatric Blepharokeratoconjunctivitis in Asian eyes. *Am J Ophthalmol.* 2012 Mar; 153(3):564-570.
4. Viswalingam M, Rauz S, Morlet N, Dart JK. Blepharokeratoconjunctivitis in Children: Diagnosis and Treatment. *Br J Ophthalmol.* 2005 Apr; 89(4):400-3
5. Hamada S, Khan I, Denniston AK, Rauz S. Childhood Blepharokeratoconjunctivitis: Characterising a severe phenotype in white adolescents. *Br J Ophthalmol.* 2012 Jul; 96(7): 949-55.
6. Wong IB, Nischal KK. Managing a Child with an External Ocular Disease. *J AAPOS.* 2010 Feb; 14(1): 86-77.